

# *Marcapasos y Anestesia*

**DR. JOSE LLAGUNES**



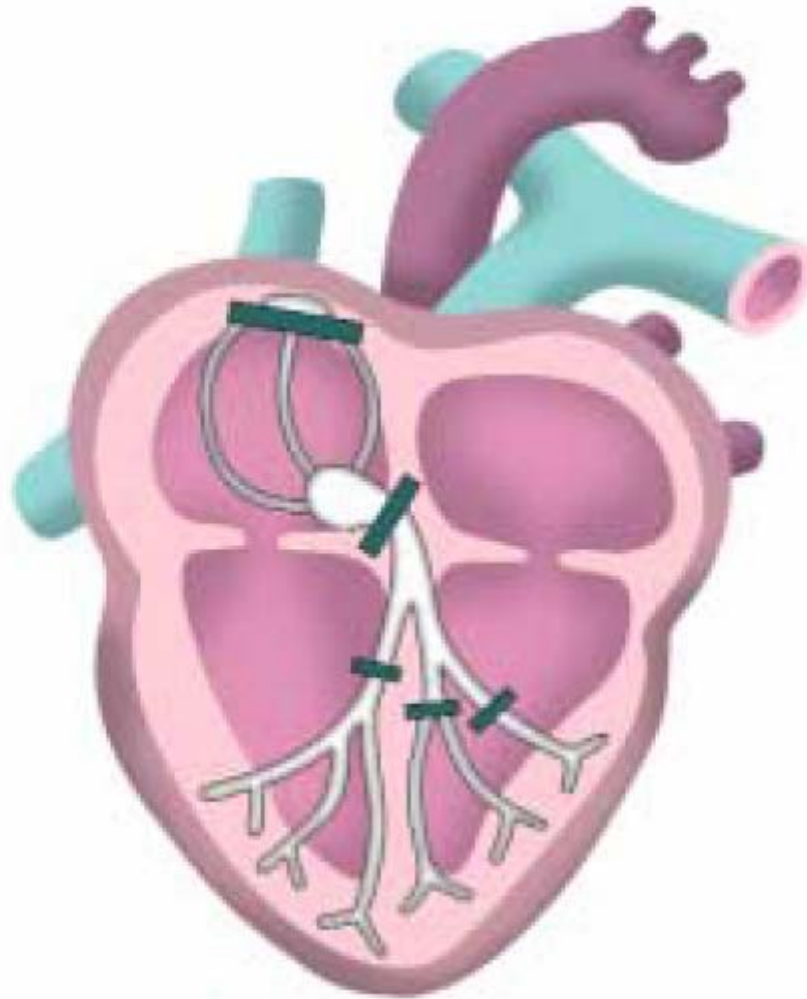
CONSORCI  
HOSPITAL GENERAL  
UNIVERSITARI  
VALÈNCIA

**Servicio de Anestesia, Reanimación y  
Tratamiento del Dolor.**

**Consorcio Hospital General  
Universitario de Valencia.**

**Sesión de Formación Continuada  
Valencia 10 de Abril 2007**

# *marcapasos y anestesia*



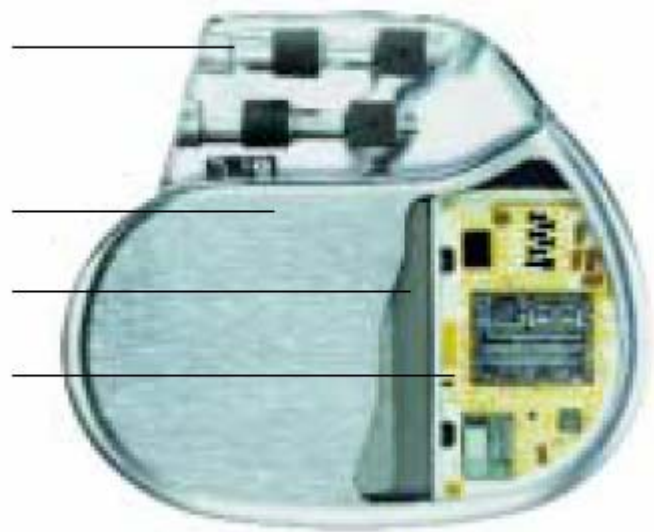
# *marcapasos y anestesia*

**Conector visible (cabezal)**

**Carcasa biocompatible de titanio**

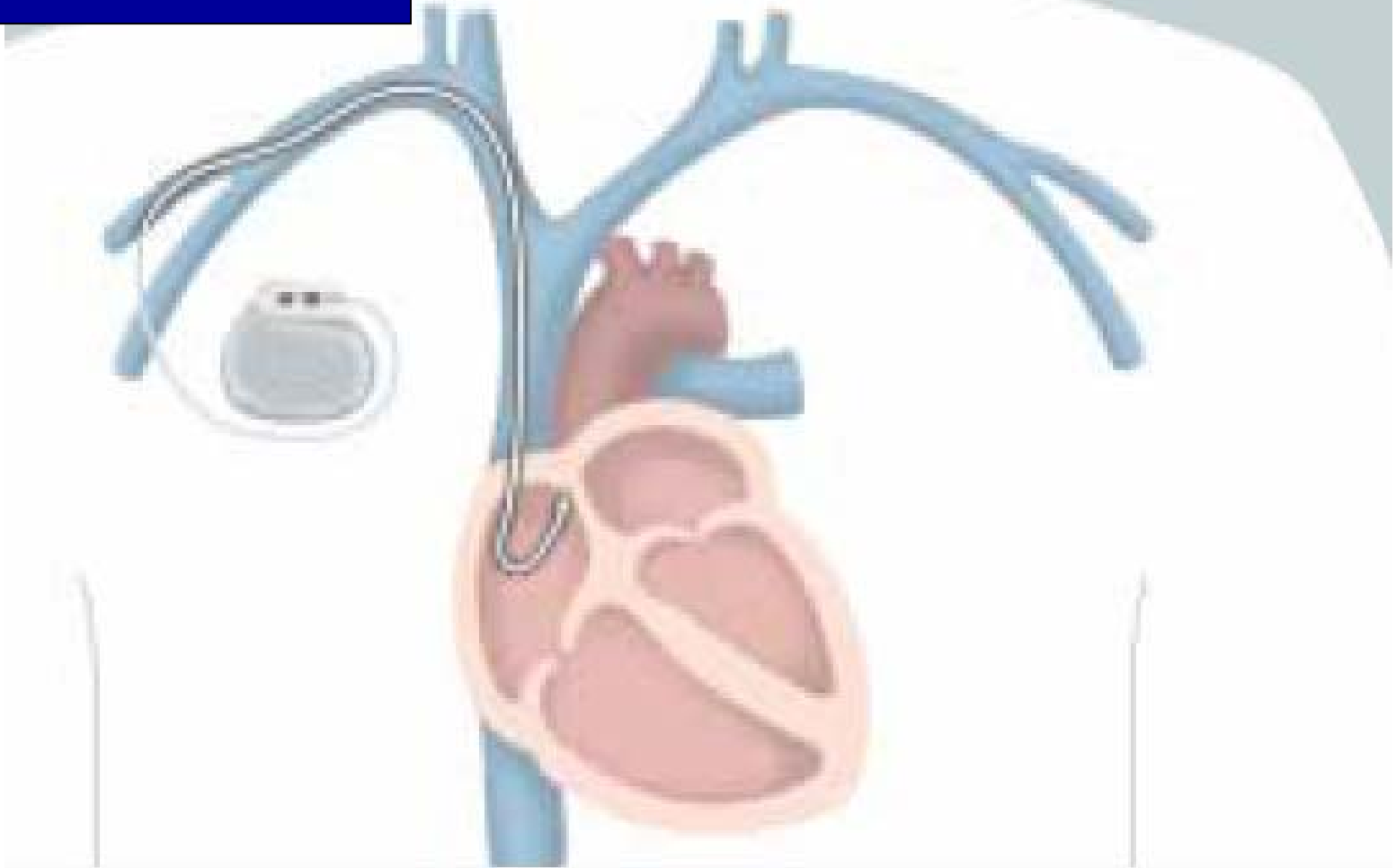**Batería especial de alta duración**

**Circuitos electrónicos**



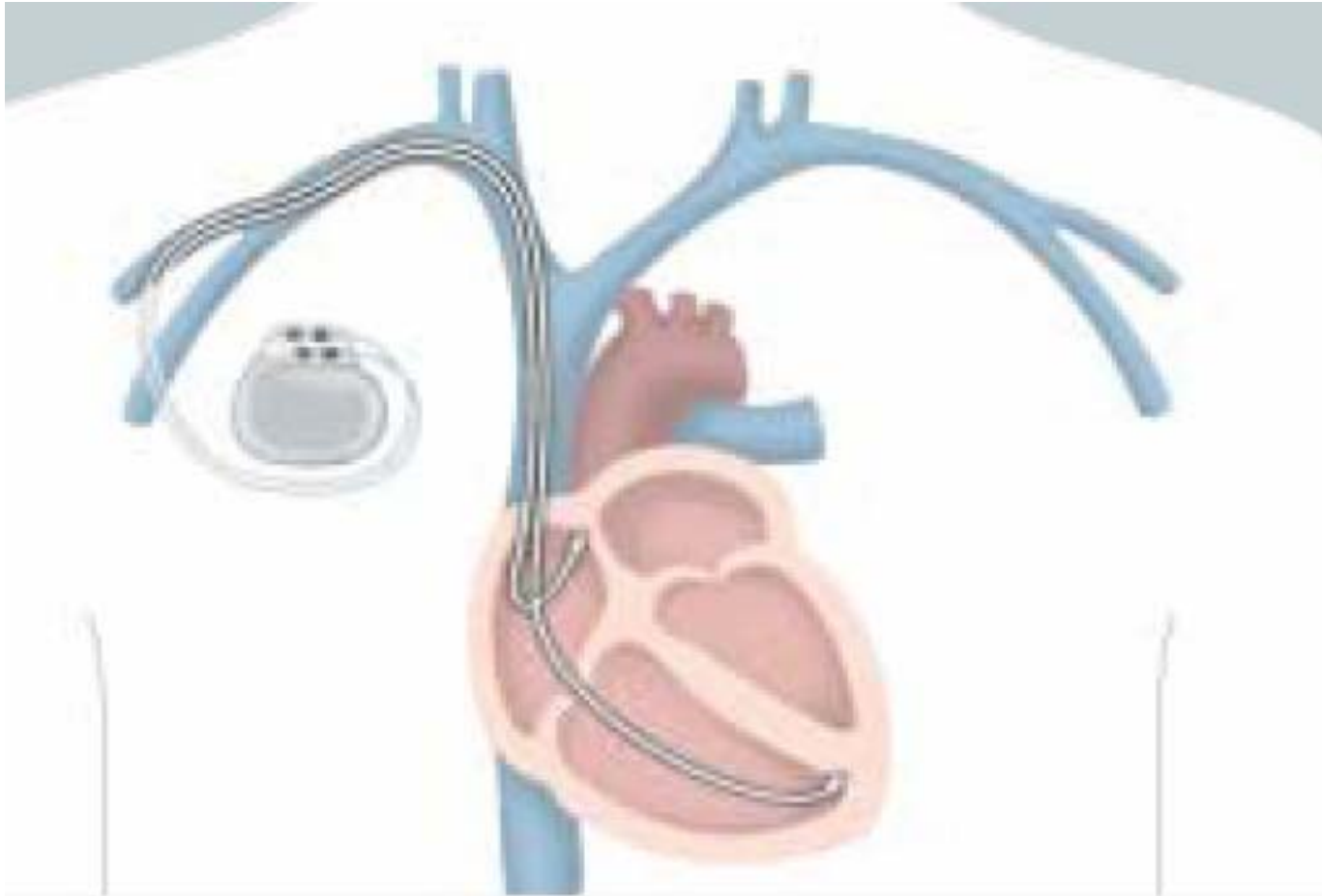
# *marcapasos y anestesia*

MCP monocameral



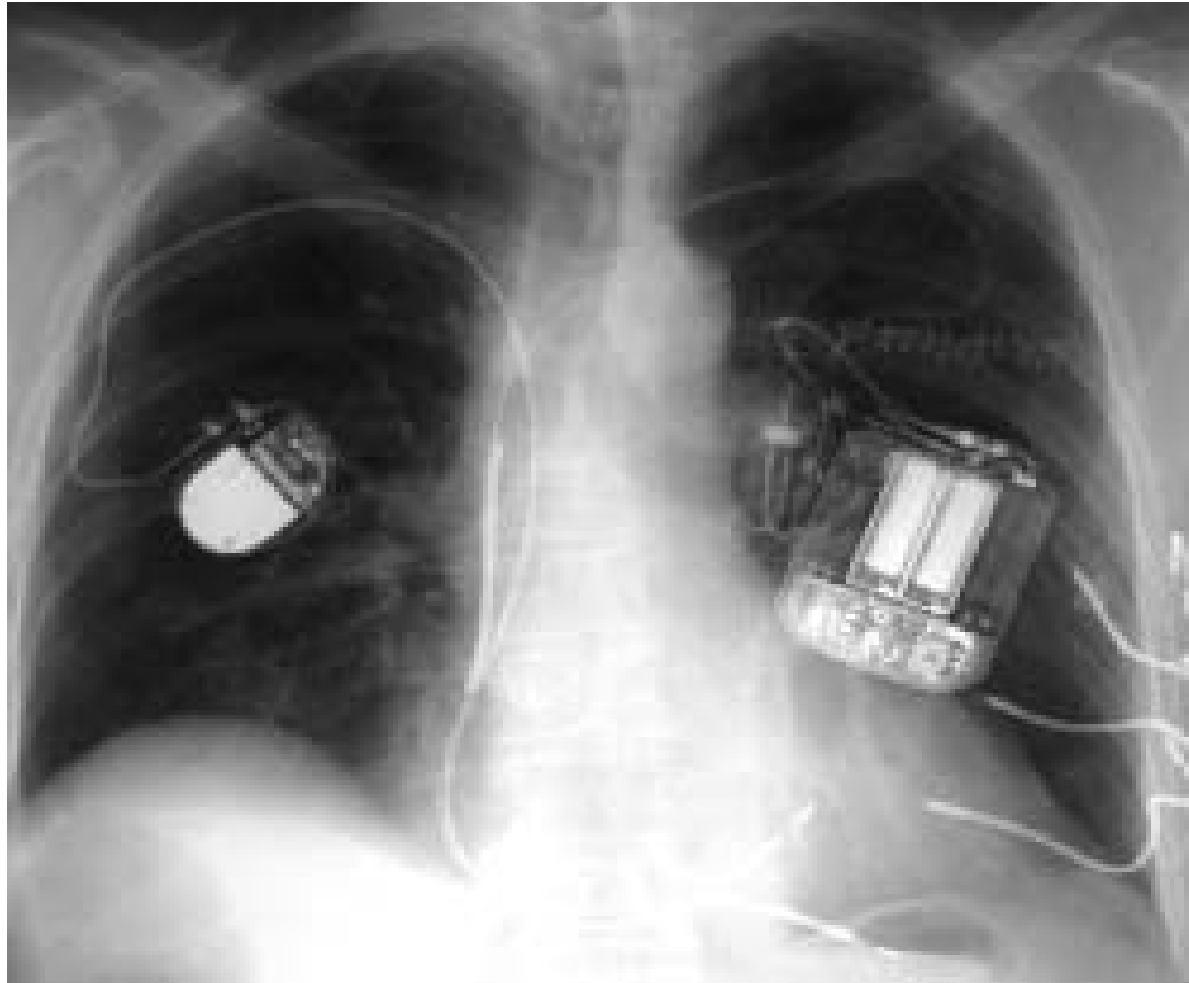# *marcapasos y anestesia*

MCP bicameral o secuencial



# *marcapasos y anestesia*

MCP nos podemos encontrar



# *marcapasos y anestesia*

## **GUIAS DE LA S.E. CARDIOLOGIA**

[http://www.revespcardiol.org/cgi-bin/wdbcgi.exe/cardio/mrevista\\_cardio.resumen?pident=10486](http://www.revespcardiol.org/cgi-bin/wdbcgi.exe/cardio/mrevista_cardio.resumen?pident=10486)

**atención:** NUEVA TERAPIA DE RESINCRONIZACION CARDIACA

# Guías implante mcp de la AHA

*Circulation.* 1998;97:1325-1335.

## ACC/AHA Practice Guidelines

### ACC/AHA Guidelines for Implantation of Cardiac Pacemakers and Antiarrhythmia Devices: Executive Summary

A Report of the American College of Cardiology/  
American Heart Association Task Force on Practice Guidelines  
(Committee on Pacemaker Implantation)

Gabriel Gregoratos, MD, FACC, Chair; Melvin D. Cheitlin, MD, FACC; Alicia Conill, MD, FACP\*;  
Andrew E. Epstein, MD, FACC; Christopher Fellows, MD, FACC;  
T. Bruce Ferguson, Jr, MD, FACC†; Roger A. Freedman, MD, FACC; Mark A. Hlatky, MD, FACC;  
Gerald V. Naccarelli, MD, FACC; Sanjeev Saksena, MD, MBBS, FACC‡;  
Robert C. Schlant, MD, FACC; Michael J. Silka, MD, FACC

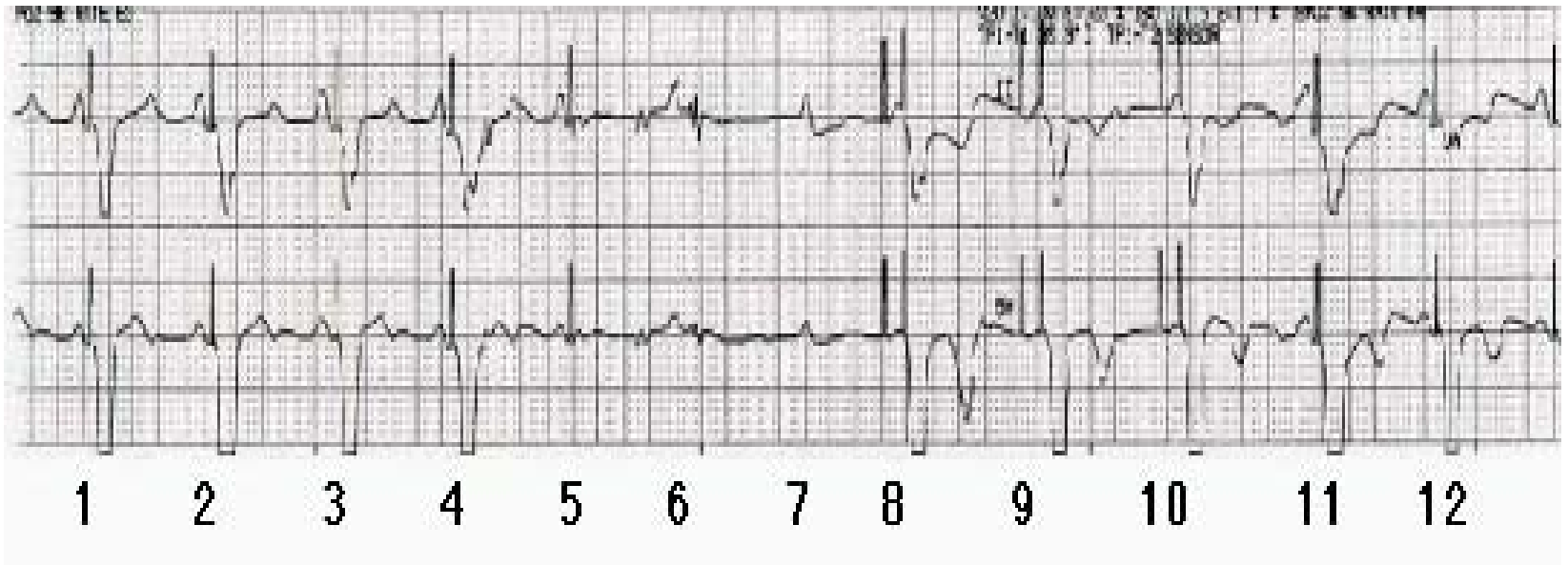
[www.cardiosource.com/guidelines](http://www.cardiosource.com/guidelines) (año2002)

ACC/AHA/NASPE 2002 Guideline Update for Implantation of  
Cardiac Pacemakers and Antiarrhythmia Devices—Full Text  
(ACC/AHA/NASPE Committee on Implantation)



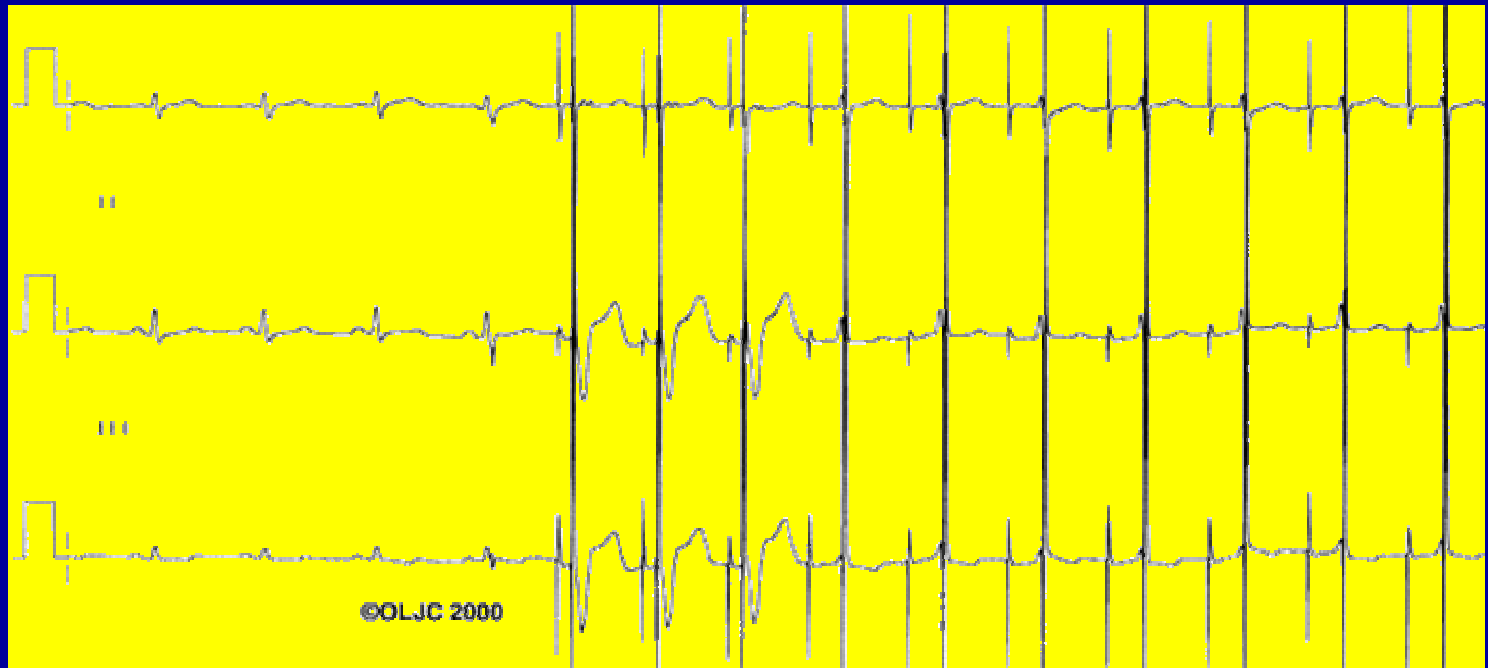
# *marcapasos y anestesia*

- Interferencias con bisturí eléctrico en paciente con mcp unipolar VVI por bloqueo A-V completo



# APLICACIÓN DE UN IMAN SOBRE MCP DDD

*Respuesta en VVI o VOO: Siempre a 99 o 101 ppm.*





**Los siguientes procedimientos son totalmente inofensivos:**

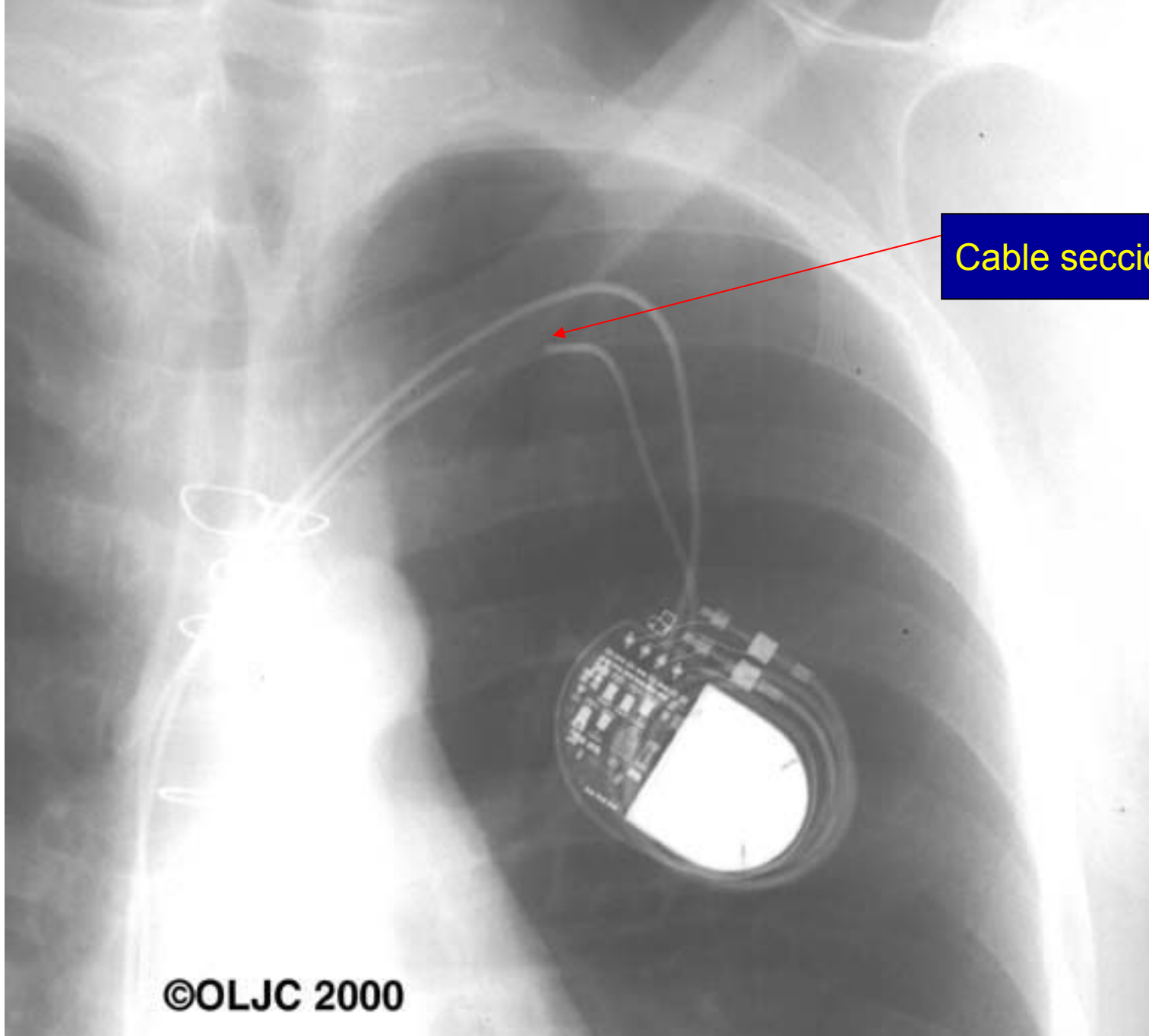
rayos X

sonografía o mamografía

tallado de la dentadura



Atención: En caso de procedimientos muy especiales como radiación, litotricia, electroestimulación nerviosa transcutánea, resonancia magnética nuclear o electrocauterio, debería llevarse a cabo antes un examen detallado en presencia de su cardiólogo.



Cable seccionado

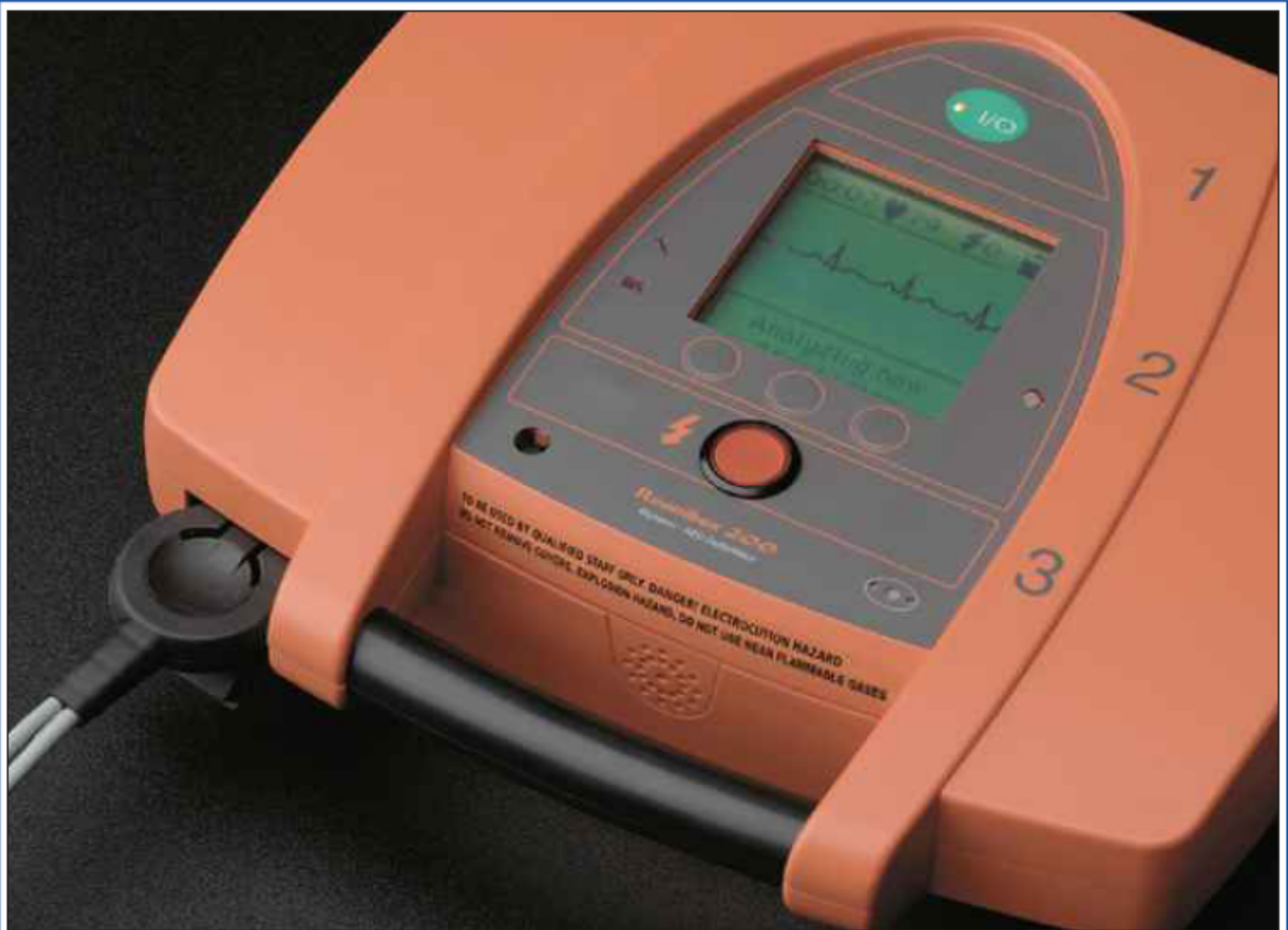# Indications of Problems with Pacemakers

---

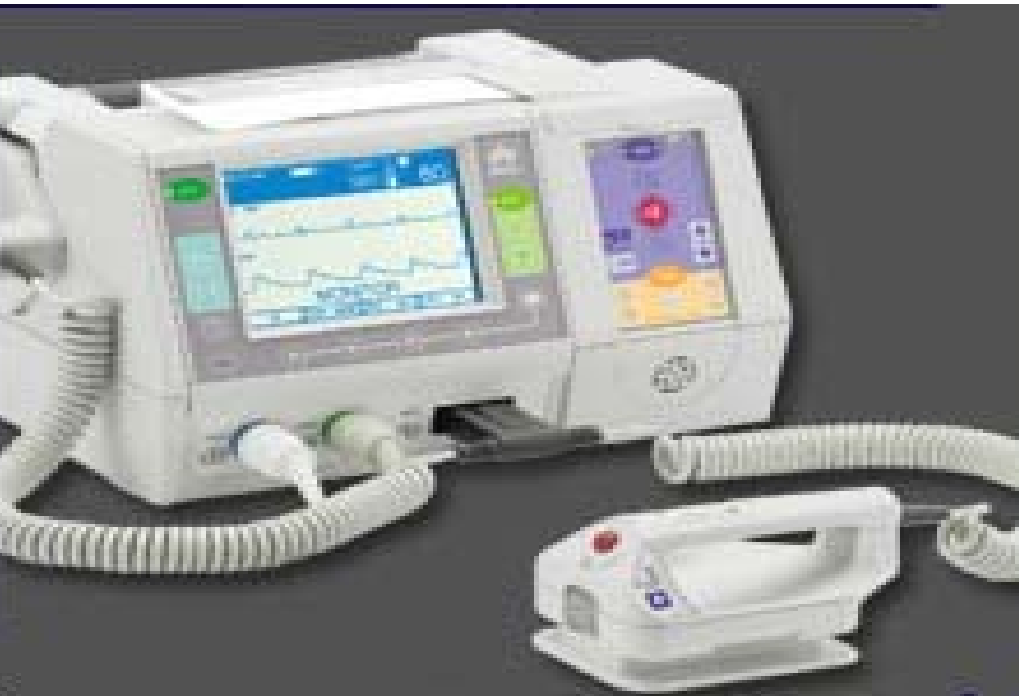In the unlikely event that your pacemaker is not functioning properly you may experience any of the following signs and symptoms:


- Recurrence of original symptoms
- Shortness of breath or difficult breathing
- Dizziness or fainting
- Prolonged weakness or fatigue
- Chest pain
- Swelling of ankles, lower legs, wrists, or lower arms
- Muscle twitching
- Prolonged or excessive hiccupping
- Redness or drainage at the incision site
- Prolonged fever

If any of these symptoms occur, check your pulse and notify your physician as soon as possible.



Automated External Defibrillator





DO NOT USE IF CHARGED FROM A FIRE, JARRED ELECTRICITY OR OTHER CAUSES  
IF YOU EXPERIENCE ANY OF THESE SYMPTOMS, STOP USING THE DEVICE IMMEDIATELY



