CONSORCI
HOSPITAL GENERAL
UNIVERSITARI
VALÈNCIA

19 de noviembre, 2019

Feocromocitoma y Paraganglioma

Sesión de revisión noviembre 2019

Fernando Alonso Ecenarro

R3 Medicina Interna

REVIEW ARTICLE FREE PREVIEW

Pheochromocytoma and Paraganglioma

Hartmut P.H. Neumann, M.D., William F. Young, Jr., M.D., and Charis Eng, M.D., Ph.D.

Pheochromocytoma and paraganglioma are related tumors that differ mainly in location; pheochromocytomas are adrenal, and paragangliomas can be anywhere else. The symptoms are protean and common, but the tumors are rare. The diagnosis may signify an underlying genetic syndrome.

August 8, 2019
N Engl J Med 2019; 381:552-565
DOI: 10.1056/NEJMra1806651

Editors

Índice

- Introducción
- Epidemiología
- Cuadro clínico
- Diagnóstico
- Tratamiento
- Conclusiones

Tumor secretor de catecolaminas que procede de células cromafines.

- **Feocromocitoma:** procede de la **médula adrenal**.
- **Paraganglioma:** procede de los ganglios simpáticos (**extraadrenal,** tejido cromafín).
- Histología predominantemente benigna **vs** Hiperproducción de catecolaminas (noradrenalina y adrenalina > dopamina)

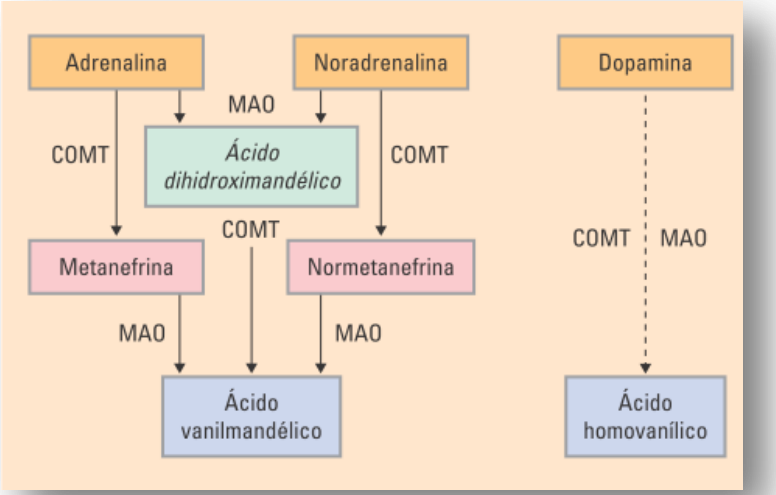

Metabolismo de catecolaminas. *Guillín C, Bernabeu I, Rodríguez-Gómez IA, Casanueva FF. Feocromocitoma y paraganglioma. Med. 2016;12(14):795–801.*

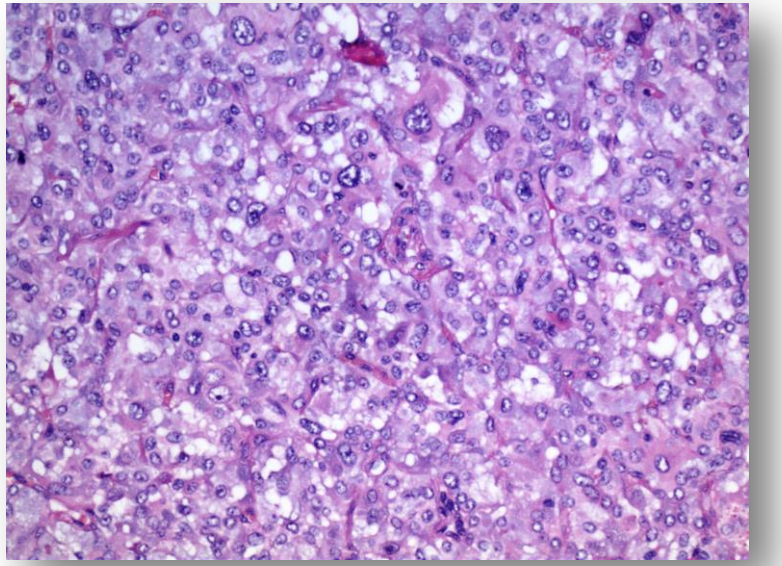

Case courtesy of Dr Andrew Ryan, Radiopaedia.org, rID: 22683

- Incidencia: 0,6 casos por cada 100.000 personas/año (Berends et al. 2018).
- Varones = Mujeres. Diagnóstico entre los 40-50 años.
- Localización:
  - 95% de los tumores secretores de catecolaminas situados en la cavidad abdominal.
  - Localizaciones extraadrenales: paraaórtica abdominal (75%), vejiga urinaria (10%), tórax (10%), cráneo, cuello y pelvis (5%).

- extraadrenales (paragangliomas).
- feocromocitomas son bilaterales.
- son malignos (sin características bioquímicas ni histológicas específicas pero con capacidad de invadir y metastatizar a distancia).
- son diagnosticados en la infancia.
- recidivan tras exéresis quirúrgica.
- son diagnosticados a raíz del hallazgo de un incidentaloma.
- causa del 0,10% de los casos de hipertensión arterial.

Triada clínica clásica:

- Cefalea (80%)
- Palpitaciones (64%)
- Diaforesis (57%)

+

Hipertensión arterial

(S 90,9%-E 93,8%)

Otros síntomas:

- Ataques de pánico
- Palidez
- Frialdad acra
- Temblor
- Retinopatía hipertensiva
- Miocardiopatía por catecolaminas
- Náuseas

- Pérdida de peso
- Estreñimiento
- Hipercalcemia
- Raynaud
- Eritrocitosis
- Hematuria indolora
- Hiperglucemia/ Diabetes

Asintomáticos:

- Incidentaloma
- Estudio genético

Endocr Rev. 2003 Aug;24(4):539-53.

Pheochromocytoma: state-of-the-art and future prospects.

Bravo EL[1], Tagle R.

DIAGNÓSTICO DIFERENCIAL

- **Cardiovascular:** arritmias, cardiopatía isquémica, hipotensión ortostática, síncope…
- **Endocrinas:** tumores carcinoides, hipertiroidismo, hipoglucemia…
- **Neurológicas:** epilepsia diencefálica, cefalea en racimos, migraña, encefalopatía hipertensiva, neoplasias, ACV de fosa posterior…
- **Psiquiátricas:** crisis de pánico, ansiedad, somatización, simulación…
- **Fármacos:** retirada de fármacos simpaticomiméticos, IMAOS + descongestionantes, síndrome del hombre rojo (vancomicina)…
- **Tóxicos:** cocaína, GHB, anfetaminas…
- **Otros:** anafilaxia idiopática recurrente, mastocitosis…

LIBERACIÓN EXCESIVA CATECOLAMINAS

- Incremento en **plasma** de metanefrinas fraccionadas (metanefrina y normetanefrina):
  S 97% y E 93%

- Incremento en **plasma** de catecolaminas fraccionadas (adrenalina, noradrenalina y dopamina): menos sensible. Aunque >2 veces el límite también diagnóstico.

JAMA. 2002 Mar 20;287(11):1427-34.

Biochemical diagnosis of pheochromocytoma: which test is best?

Lenders JW[1], Pacak K, Walther MM, Linehan WM, Mannelli M, Friberg P, Keiser HR, Goldstein DS, Eisenhofer G.

Conclusions

Plasma free metanephrines constitute the best test for excluding or confirming pheochromocytoma and should be the test of first choice for diagnosis of the tumor. A negative test result virtually excludes pheochromocytoma. In such patients, representing more than 80% of those tested, no immediate further tests for the tumor are necessary. Furthermore, in about 80% of patients with pheochromocytoma, the magnitude of increase in plasma free metanephrines is so large that the tumor can be confirmed with close to 100% probability. In these patients, the immediate task is to locate the tumor.

- **Otras:**
  - Orina de 24h.
  - Cromogranina A.
  - Prueba de supresión con clonidina

- **Situaciones clínicas:** estrés, edad avanzada, hipoglucemia.
- **Medicación:** ansiolíticos, antidepresivos tricíclicos y antipsicóticos, catecolaminas y agonistas adrenérgicos, interrupción de clonidina, anfetaminas, levodopa, fenoxibenzamina, betabloqueantes, buspirona hidralacina, minoxidil.
- **Otras sustancias:** nicotina, cafeína, etanol, cocaína.

3 escenarios

LOCALIZACIÓN ANATÓMICA

Síntomas típicos

1. Medir metanefrinas en plasma

2. Realizar TAC abdominal con contraste/ base del cráneo, cuello, tórax y pelvis.

Incidentaloma

(Masa con atenuación >10 Hounsfield)

1. Prueba de imagen
   - TAC ≤ 10 HU se descarta feocromocitoma
   - TAC > 10 HU se deben realizar metanefrinas

2. Si metanefrinas patológicas se debe realizar estudio de imagen con contraste

Portador de mutación

1. Medir metanefrinas +/- realizar prueba de imagen

2. Test genético

Neumann, H. P., Young, W. F., & Eng, C. (2019). Pheochromocytoma and Paraganglioma. *The New England Journal of Medicine*, *381*(6), 552–565.

Portador de mutación

1. Medir metanefrinas +/- realizar prueba de imagen

Table 1. Approach to Pheochromocytoma and Associated Syndromes According to the Clinical Scenario.*

Clinical Scenario	Initial Biochemical Testing and Imaging	Follow-up Biochemical Testing and Imaging
Signs and symptoms on presentation (e.g., resistant hypertension or paroxysms of hypertension, palpitations, perspiration, headaches, and markedly elevated metanephrines or catecholamines)	Perform abdominal contrast-enhanced CT or MRI; if abdominal imaging is negative, consider MRI of skull base, neck, chest, and pelvis	Measure metanephrines postoperatively and then annually; if bilateral pheochromocytomas were removed with cortical-sparing surgery, document normal glucocorticoid secretory function with cosyntropin-stimulation test
Incidentally discovered adrenal or retroperitoneal mass with attenuation >10 Hounsfield units on unenhanced CT	If levels of metanephrines are clearly elevated, perform contrast-enhanced CT or MRI; if mass is >10 cm in diameter or is extraadrenal, search for additional paragangliomas or metastatic disease with ^{123}I-MIBG scintigraphy, ^{68}Ga-DOTATATE–PET–CT, or ^{18}F-FDG–PET–CT	If a pheochromocytoma or paraganglioma was resected, measure metanephrines postoperatively and then annually
Patient identified as carrier of disease-causing mutation		
RET mutation	Measure metanephrines and perform abdominal MRI; measure serum calcitonin and calcium; seek endocrine surgery consultation if thyroid gland not previously resected	Measure serum calcitonin, metanephrines, and serum calcium annually
VHL mutation	Measure metanephrines; perform MRI of the brain, spinal cord, and abdomen; perform ophthalmoscopy	Measure metanephrines yearly; perform MRI of the brain, spinal cord, and abdomen; perform ophthalmoscopy; if no tumor found, monitor every 2 or 3 years
SDHA, *SDHB*, or *SDHD* mutation	Perform MRI of skull base and neck, thorax, retroperitoneum, and pelvis; alternatively, perform ^{68}Ga-DOTATATE–PET–CT; also measure metanephrines	Measure metanephrines yearly; if a pheochromocytoma or paraganglioma was removed, perform MRI of the surgical region annually for yr 1–3; for body areas that had no tumors, perform MRI every 3 yr
SDHC or *SDHAF2* mutation	Measure metanephrines; perform MRI of skull base and neck or ^{68}Ga-DOTATATE–PET–CT	If a paraganglioma or pheochromocytoma was removed, perform MRI of the surgical region annually for yr 1–3; for body areas that had no tumors, perform MRI every 3 to 5 yr
MAX or *TMEM127* mutation	Measure metanephrines; perform MRI of the abdomen or ^{68}Ga-DOTATATE–PET–CT	Measure metanephrines yearly; if a pheochromocytoma or paraganglioma was removed, perform MRI of the surgical region annually for yr 1–3; perform MRI of the abdomen every 3 yr
Neurofibromatosis type 1	Measure metanephrines	If hypertension or clinical symptoms develop, measure metanephrines

* The term metanephrines refers to metanephrine and normetanephrine. CT denotes computed tomography, ^{18}F-FDG ^{18}F-fluorodeoxyglucose, ^{68}Ga-DOTATATE ^{68}Ga-labeled 1,4,7,10-tetraazacyclododecane–1,4,7,10-tetraacetic acid–octreotate, ^{123}I-MIBG ^{123}I-labeled metaiodobenzylguanidine, MRI magnetic resonance imaging, and PET positron-emission tomography.

LOCALIZACIÓN ANATÓMICA

- **Técnicas iniciales de elección:**
  - TAC: S 85-95% y E 65-75% si masas superiores a 1cm. > 20 HU. Lavado < 50%.
  - RMN abdominal: S 100% y E 65-75%. Hiperintesos en T2.

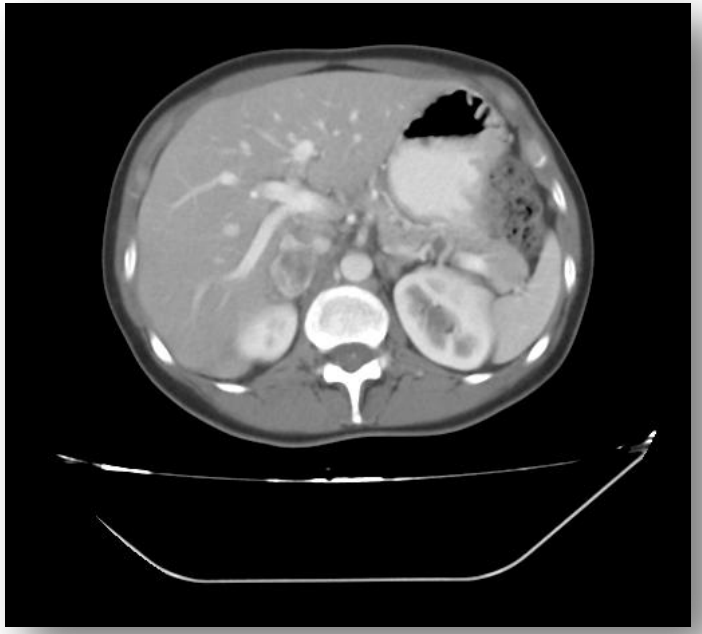

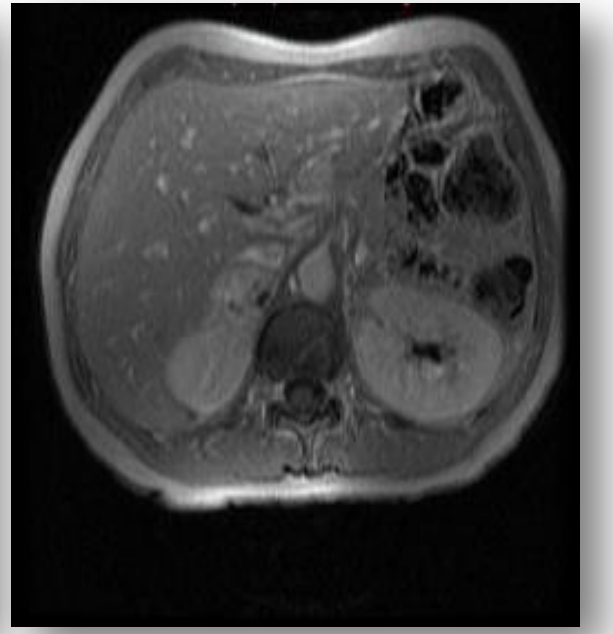

SERAM 2010. Borrego Gómez, Jesús; Martel Villagrán, José; Mitjavila casanovas, Mercedes; Carrero Alvaro, Juan; Camacho Romero, Jonathan; Marxias Martín, Montserrat. Luces y sombras del feocromocitoma. ¿Es posible aproximarse con seguridad a su diagnóstico por imagen?

LOCALIZACIÓN ANATÓMICA

¿Malignidad? = **Tumor metastásico**

- **Feocromocitoma:** Hueso y Ganglios
- **Paraganglioma:** Hígado y pulmones

- **Técnicas funcionales:**
  - Gammagrafía I metayodobenziguanidina (MIBG): S 80% y E 90%. Feocromocitomas > 10 cm y/o con riesgo de malignidad.
  - PET con FDOPA: sospecha de malignidad / Síndromes genéticos.

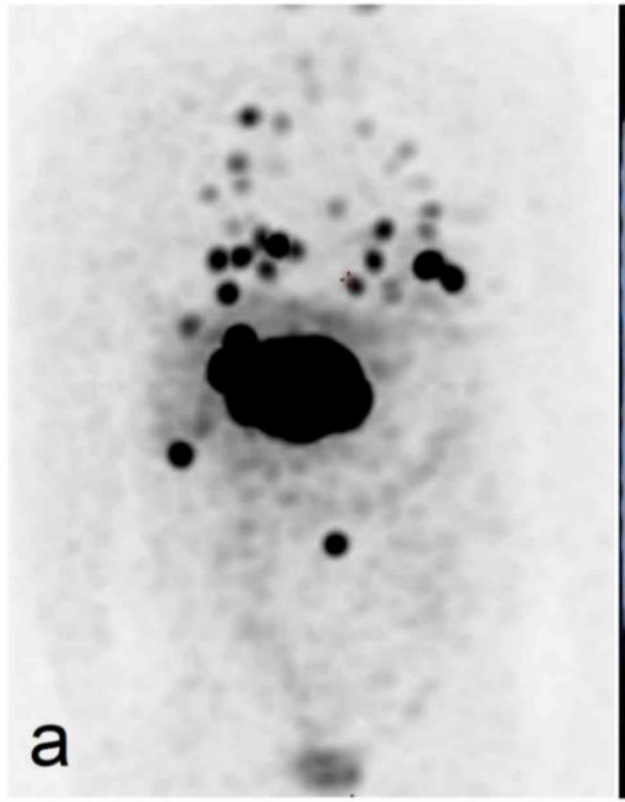

Čtvrtlík F, Koranda P, Schovánek J, Škarda J, Hartmann I, Tüdös Z. Current diagnostic imaging of pheochromocytomas and implications for therapeutic strategy (Review). Vol. 15, Experimental and Therapeutic Medicine. Spandidos Publications; 2018. p. 3151–60.

Síndromes asociados

Table 2. Characteristics of Pheochromocytoma-Associated Syndromes.*

Gene	Syndrome	Nonchromaffin Tumors	Transmission	Adrenal Tumors	Head and Neck Tumors	Extraadrenal Tumors†	Multiple Tumors	Metastatic Tumors‡	Family History§
						frequency (percent)			
VHL	VHL	Retinal and CNS hemangioblastomas, RCC, pancreatic neuroendocrine tumor, ELST	Autosomal dominant	>50	<1	10–24	>50	1–9	25–50
NF1	NF1	Cutaneous neurofibromas, malignant peripheral-nerve-sheath tumor, breast cancer	Autosomal dominant	>50	<1	1–9	25–50	1–9	10–24
RET	MEN-2	Medullary thyroid carcinoma, hyperparathyroidism	Autosomal dominant	>50	<1	<1	>50	<1	25–50
SDHA	PGL5	Rarely also pituitary adenoma, GIST, RCC	Autosomal dominant	25–50	25–50	25–50	1–9	1–9	1–9
SDHB	PGL4	Rarely also pituitary adenoma, GIST, RCC	Autosomal dominant	25–50	25–50	25–50	10–24	25–50	10–24
SDHC	PGL3	Rarely also pituitary adenoma, GIST	Autosomal dominant	1–9	>50	<1	10–24	Not reported	10–24
SDHD	PGL1	Rarely also pituitary adenoma, GIST, RCC	Autosomal dominant, maternal imprinting	10–24	>50	10–24	>50	1–9	25–50
SDHAF2	PGL2		Autosomal dominant, maternal imprinting	1–9	>50	Not reported	>50	Not reported	>50
MAX	No name	Rarely also RCC	Autosomal dominant	>50	<1	1–9	>50	1–9	25–50
TMEM127	No name		Autosomal dominant	>50	1–9	<1	25–50	10–24	1–9

* For multiple endocrine neoplasia type 2 (MEN-2), von Hippel–Lindau disease (VHL), and neurofibromatosis type 1 (NF1), the frequencies of the characteristics shown are for patients with chromaffin tumors, since such tumors do not develop in all patients with these syndromes. CNS denotes central nervous system, ELST endolymphatic-sac tumor of inner ear, GIST gastrointestinal stromal tumor, HPT hyperparathyroidism, PGL paraganglioma syndrome (PGL1 through PGL5 denote paraganglioma syndromes 1 through 5), and RCC renal-cell carcinoma.
† These tumors consist of retroperitoneal, pelvic, and thoracic tumors.
‡ These tumors consist of metastatic pheochromocytoma and paraganglioma.
§ Shown is the frequency of a family history of components of the given syndrome.

De elección: TRATAMIENTO QUIRÚRGICO

Study Type:	Interventional (Clinical Trial)
Estimated Enrollment:	60 participants
Allocation:	Randomized
Intervention Model:	Parallel Assignment
Masking:	None (Open Label)
Primary Purpose:	Treatment
Official Title:	Randomized Controlled Trial of Preoperative Alpha Blockade for Pheochromocytoma
Actual Study Start Date:	May 5, 2017
Estimated Primary Completion Date:	May 2023
Estimated Study Completion Date:	May 2024

- **Bloqueo alfa adrenérgico:**
  - **T:** 10-14 días preprocedimiento.
  - **O:** Normalizar PA y expandir volemia.
  - **Pauta:**
    - **Fenoxibenzamina** 10 mg 1 ó 2 veces cada 24h.
      - Incrementar hasta controlar paroxismos y PA.
    - **Doxazosina** 1 mg de inicio.
    - 48-72 h tras inicio aumentar aporte de Na (5g/día).
- **Bloqueo beta adrenérgico:**
  - **T:** 2-3 días antes de Qx. Primero el alfa.
  - **O:** Controlar Frecuencia cardíaca.
  - **Pauta:**
    - **Metoprolol** 25 mg c/ 24h.
      - Fc objetivo: 60-80 lpm.
- Bloqueadores de canales de Calcio: Suplementación alfa y beta.
  - Nicardipino 30 mg 2 c/24h.
- Inhibidores de la síntesis de catecolaminas: Metirosina. Fracaso de los anteriores.

De elección: TRATAMIENTO QUIRÚRGICO

Br J Anaesth. 2017 Feb;118(2):182-189. doi: 10.1093/bja/aew392.

Perioperative α-receptor blockade in phaeochromocytoma surgery: an observational case series.

Groeben H[1], Nottebaum BJ[2], Alesina PF[3], Traut A[4], Neumann HP[5], Walz MK[3].

- Serie de casos observacional:
  - 110 pacientes alfa bloqueo.
  - 166 pacientes sin bloqueo.
- No se mostraban evidencias significativas:
  - PAs intraoperatoria
  - Episodios Hipertensivos
  - Complicaciones mayores

- Guías 2014 Endocrine Society mantienen la indicación de bloqueo preoperatorio.

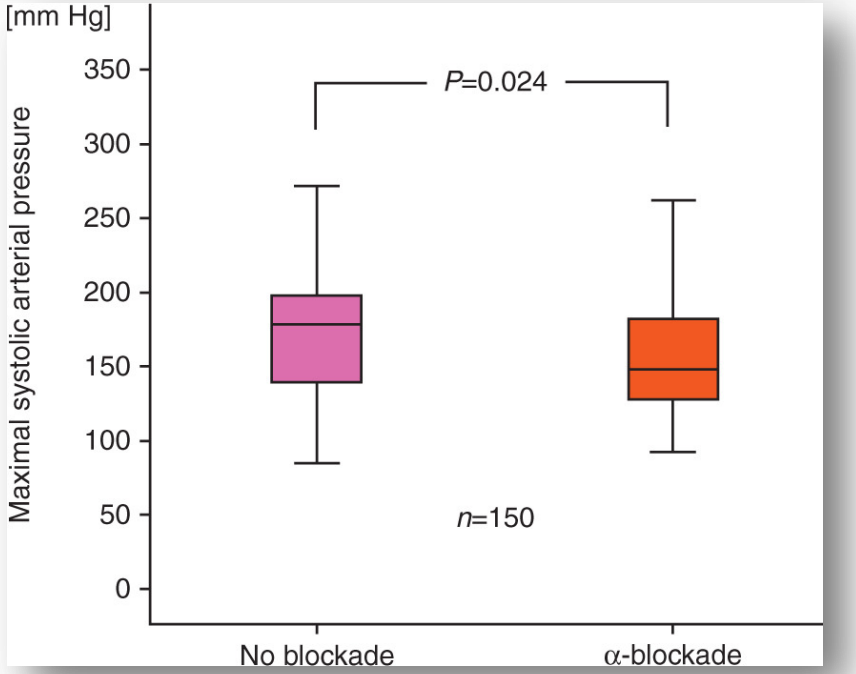

De elección: TRATAMIENTO QUIRÚRGICO

ADRENALECTOMÍA

Surgery. 1996 Dec;120(6):1076-9; discussion 1079-80.

Is laparoscopic adrenalectomy indicated for pheochromocytomas?

Gagner M[1], Breton G, Pharand D, Pomp A.

- Evitar fármacos que liberen catecolaminas: morfina/fentanilo/quetamina.
- Abordaje de elección < 8 cm: laparoscópico (transabdominal/retroperitoneal/transperitoneal).
- Asegurar si feocromocitoma bilateral: SUPLEMENTACIÓN.

¿Seguimiento?

Table 1. Approach to Pheochromocytoma and Associated Syndromes According to the Clinical Scenario.*

Clinical Scenario	Initial Biochemical Testing and Imaging	Follow-up Biochemical Testing and Imaging
Signs and symptoms on presentation (e.g., resistant hypertension or paroxysms of hypertension, palpitations, perspiration, headaches, and markedly elevated metanephrines or catecholamines)	Perform abdominal contrast-enhanced CT or MRI; if abdominal imaging is negative, consider MRI of skull base, neck, chest, and pelvis	Measure metanephrines postoperatively and then annually; if bilateral pheochromocytomas were removed with cortical-sparing surgery, document normal glucocorticoid secretory function with cosyntropin-stimulation test
Incidentally discovered adrenal or retroperitoneal mass with attenuation >10 Hounsfield units on unenhanced CT	If levels of metanephrines are clearly elevated, perform contrast-enhanced CT or MRI; if mass is >10 cm in diameter or is extraadrenal, search for additional paragangliomas or metastatic disease with ^{123}I-MIBG scintigraphy, ^{68}Ga-DOTATATE–PET–CT, or ^{18}F-FDG–PET–CT	If a pheochromocytoma or paraganglioma was resected, measure metanephrines postoperatively and then annually
Patient identified as carrier of disease-causing mutation		
RET mutation	Measure metanephrines and perform abdominal MRI; measure serum calcitonin and calcium; seek endocrine surgery consultation i thyroid gland not previously resected	Measure serum calcitonin, metanephrines, and serum calcium annually
VHL mutation	Measure metanephrines; perform MRI of the brain, spinal cord, and abdomen; perform ophthalmoscopy	Measure metanephrines yearly; perform MRI of the brain, spinal cord, and abdomen; perform ophthalmoscopy; if no tumor found, monitor every 2 or 3 years
SDHA, *SDHB*, or *SDHD* mutation	Perform MRI of skull base and neck, thorax, retroperitoneum, and pelvis; alternatively, perform ^{68}Ga-DOTATATE–PET–CT; also measure metanephrines	Measure metanephrines yearly; if a pheochromocytoma or paraganglioma was removed, perform MRI of the surgical region annually for yr 1–3; for body areas that had no tumors, perform MRI every 3 yr
SDHC or *SDHAF2* mutation	Measure metanephrines; perform MRI of skull base and neck or ^{68}Ga-DOTATATE–PET–CT	If a paraganglioma or pheochromocytoma was removed, perform MRI of the surgical region annually for yr 1–3; for body areas that had no tumors, perform MRI every 3 to 5 yr
MAX or *TMEM127* mutation	Measure metanephrines; perform MRI of the abdomen or ^{68}Ga-DOTATATE–PET–CT	Measure metanephrines yearly; if a pheochromocytoma or paraganglioma was removed, perform MRI of the surgical region annually for yr 1–3; perform MRI of the abdomen every 3 yr
Neurofibromatosis type 1	Measure metanephrines	If hypertension or clinical symptoms develop, measure metanephrines

* The term metanephrines refers to metanephrine and normetanephrine. CT denotes computed tomography, ^{18}F-FDG ^{18}F-fluorodeoxyglucose, ^{68}Ga-DOTATATE ^{68}Ga-labeled 1,4,7,10-tetraazacyclododecane–1,4,7,10-tetraacetic acid–octreotate, ^{123}I-MIBG ^{123}I-labeled metaiodobenzylguanidine, MRI magnetic resonance imaging, and PET positron-emission tomography.

Recurrencias: 6,5-16,5%

- ***Metanefrinas:***
  - 1 mes
  - 6 meses
  - 1 año (10 años)
- Imagen: regularmente 3 años.
- Imagen funcional: si elevan metanefrinas.

- Se ha producido una **importante evolución** en el diagnóstico y tratamiento del feocromocitoma.
- La **presentación clínica** abarca la sintomatología clásica, los incidentalomas y el estudio genético.
- El test bioquímico de elección actualmente son las **metanefrinas** en **plasma**, dejando de lado los test en orina de 24h.
- Las pruebas de imagen de elección para un abordaje inicial son **el TAC y la RMN** con contraste.
- **El tratamiento farmacológico preoperatorio** con alfabloqueo sigue siendo de elección, con datos que apuntan a la no superioridad sobre el no tratamiento.
- El abordaje quirúrgico de elección es la **laparoscopia transperitoneal**.
- Es necesario estudiar la presencia de **síndromes asociados** ya que modificarán el seguimiento.

Muchas gracias por vuestra atención